

Conference Paper

Orthodontic Procedures after Trauma

Henry W. Fields, DDS, MS, MSD¹ • John R. Christensen, DDS, MS, MS²

Abstract: *This review considers oral trauma and its relationship to orthodontics with respect to prevention and primary, secondary, and tertiary care. The level of evidence is not high in regard to this topic, but recommendable approaches to trauma at each stage are discussed on the basis of available literature and published guidelines. Simplified biomechanics are presented to aid treatment. (Pediatr Dent 2013;35:175-83)*

KEYWORDS: ORTHODONTICS, TRAUMA

This article reviews the available evidence regarding orthodontics as an adjunct to post-oral trauma treatment for permanent teeth. The context of oral trauma injury prevalence related to the population and orthodontic practice as well as preventive measures is provided. Adjunctive orthodontic treatment is subdivided into those interventions that can be used at or near the time of the trauma, those available for longer posttrauma treatment, and those for patients in active orthodontic treatment. Criteria are provided to evaluate sensible biomechanical options. Finally, long-term solutions for traumatic injuries related to orthodontics are briefly discussed.

Although it is cited when possible, the level of evidence is not high in the available and reported literature. This leaves the clinician in a position of having to judge our potentially biased or anecdotal-based recommendations until more worthy evidence emerges.

Epidemiology of Dental Trauma from the Orthodontic Perspective

Dental trauma has been associated with protrusive maxillary anterior teeth for decades. Originally, the association was believed to be between class II malocclusions and trauma. The earliest studies began to report the relationship in the mid-1940s.¹

Studies have been continuously published that support the increased risk of trauma with increasing overjet and inadequate lip coverage. Forsberg and Tedestam² reported on etiologic and other predisposing factors related to traumatic injuries to permanent teeth in 1993. Their results showed that an angle class II malocclusion, an overjet exceeding 4 mm, a short upper lip, incompetent lips, and mouth breathing were all factors that increased susceptibility to traumatic dental injury. Bauss et al³ reported similar findings in a 2008 article. Increased overjet and inadequate lip coverage seemed to double the risk of trauma to the patient (Fig. 1). Because of the large number of studies supporting increased overjet and inadequate lip coverage as risk factors for upper incisor trauma, the logical reaction is to either protect those teeth or move them from harm's way.

¹Dr. Fields at the Division of Orthodontics, College of Dentistry, The Ohio State University, and Department of Dentistry, Nationwide Children's Hospital, Columbus, Ohio; and ²Dr. Christensen at the School of Dentistry, University of North Carolina at Chapel Hill, Chapel Hill, and Private Practice, Durham, N.C., USA.

Correspond with Dr. Fields at fields.31@osu.edu

Prevention of Dental Trauma for the Active or Potential Orthodontic Patient

Biomechanical prevention of oral trauma (mouth guards) is supported by the American Dental Association^{4,5} and most studies that have evaluated the results of mouth guard intervention⁶. The same recommendations regarding mouth guards are accepted for active orthodontic patients; the one worn properly is the most effective one.⁷ Most likely, the same issues surround their use with orthodontic patients: compliance or a lack of it, types of materials, and methods of construction. There is no reason to believe that compliance will be higher in orthodontic patients.⁸ Custom mouth guards are generally judged as more comfortable by all users. Manufacturers and suppliers tout their unique products. Some materials are more popular because of their physical characteristics and manipulability (ethylene vinyl acetate), and some designs (laminated) have provided better data in the laboratory, but convincing clinical data are missing. All authors are in agreement that a different design is appropriate for active orthodontic patients. That design should not lock the teeth in position in the mouth guard but have a smooth, flat occlusal surface so tooth movement can continue, and soft tissue and appliances require protection⁷ (Fig. 2). Therefore, the most commonly used mouth guard, the boil and bite (Fig. 3), is not fully appropriate unless it is refit at short intervals, which is inconvenient. In addition, designs with upper and lower lip and cheek protection may have some benefit, and those without that attribute are considered inappropriate by athletic rule makers for some sports when full upper and lower orthodontic appliances are used (Fig. 4).⁹ A great deal of emphasis has been placed on the role of the mouth guard to prevent concussion injuries. This evidence is equivocal⁷, but it is important to stress the importance of the mouth guard in prevention of oral injuries.

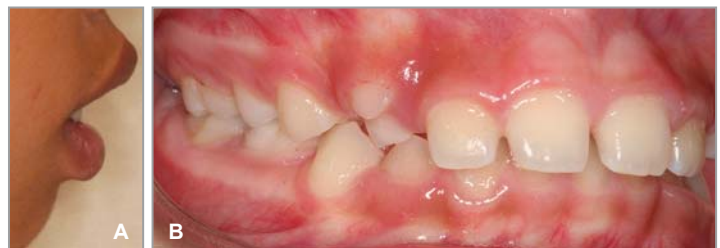

Figure 1. Patient exhibiting the classic trauma susceptible features of (A) inadequate lip coverage of the incisors and (B) increased overjet.

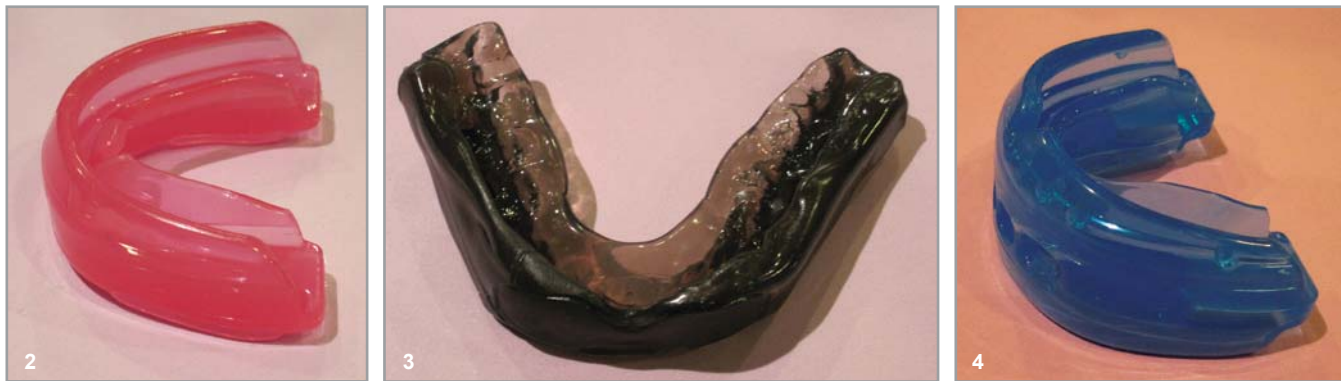

Figure 2. Example of a smooth occlusal surface and no indentations to lock in the teeth and reduce movement (Shock Braces Mouth Guard; Shock Doctor North America, Minneapolis, Minnesota).

Figure 3. A standard boil and bite mouth guard with indentations for the teeth. This is considered inappropriate for athletes with orthodontic appliances (Shock Mouth Guard; Shock Doctor North America, Minneapolis, Minnesota).

Figure 4. Example of a double mouth guard that protects both upper and lower soft tissue and is required for wrestling by the National Federation of State High School Associations for athletes with both upper and lower braces (Shock Doctor Double Braces Strapless Mouth Guard; Shock Doctor North America, Minneapolis, Minnesota).

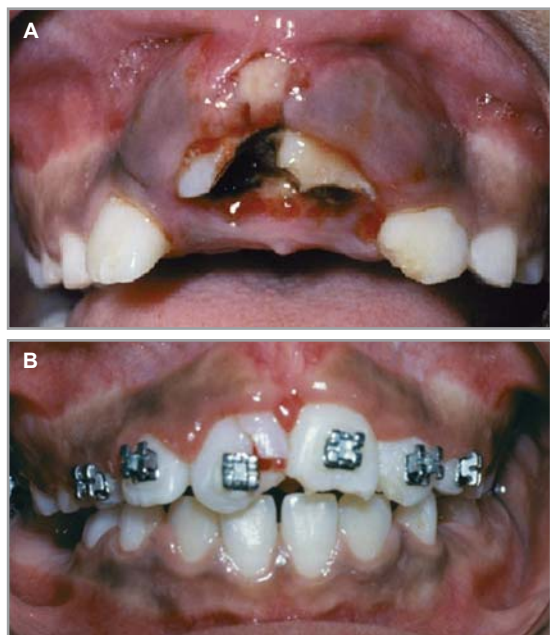


Figure 5. (A) Before orthodontic extrusion, the full extent of the dental injuries was not known. (B) Access to the clinical crown of the tooth changed the course of treatment.

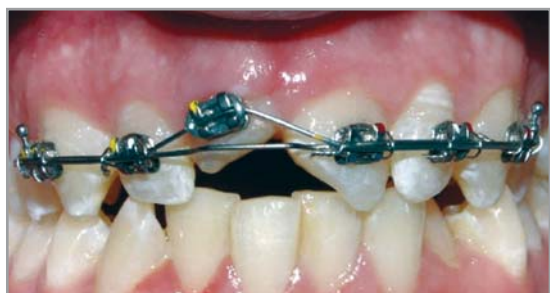

Figure 6. Patient with dental trauma and a lingual lateral luxation. Note the flexible overlay wire and the rigid base wire that will provide facial tooth movement. (From Proffit WR, Fields HW, Sarver DM. Contemporary Orthodontics, 5th ed. St Louis, MO: Mosby; 2013.)

Some have reviewed the data that indicate that overjet is a critical factor associated with the increased prevalence of oral trauma and concluded that early orthodontic treatment to retract the incisors or early reduction of the overjet by growth modification should reduce the incidence of oral trauma. The prevalence of traumatic injuries in prospective orthodontic patients evaluated in a clinical setting indicates that, as a group, they have a similar prevalence of previous oral trauma compared with the general population (approximately 10%–13%), with infractions, enamel, and enamel-dentin fractures being most common (nearly 80%).¹⁰

In the prospective randomized clinical trials completed at the University of North Carolina¹¹ and the University of Florida¹², both groups had patient pools with mean ages of 9+ years and class II malocclusion with 5–7 mm of minimum overjet. These patients had prestudy trauma prevalence of 29% and 25%, respectively, and intrastudy trauma of 23% and 28%, respectively. This is clearly a group susceptible to multiple trauma events, because on the average, a disproportionate subgroup sustained their first trauma before age 9, which makes them 8.4 times more likely to have multiple events.¹³ When clearly using trauma-prone groups, both studies found no differences in the proportion of new trauma among the groups, but there was a significant increase in the control group trauma during phase 1 in the University of North Carolina study. In light of those results, potential costs, the extremely early starting time required in the mixed dentition, and no definitive prospective randomized clinical trial data focused on oral trauma, there appears to be little evidence to recommend routine early orthodontic treatment for increased overjet as a preventive measure.

Orthodontics as an Adjunct to Posttrauma Treatment

Treatment of anterior tooth trauma can be categorized as primary, secondary, or tertiary care.¹⁴ Treatment recommendations for all types of primary and secondary posttrauma care have become more standardized.¹⁵ A website has been designed to help the clinician make the proper diagnosis and follow the appropriate treatment given the diagnosis.¹⁶ The development of this website has been a boon to clinicians to share trauma data, experiences, and recommendations for treatment. Unfortunately, trauma comes in many forms and does not always fit into distinct categories. In addition, the variable of “time” plays a role in the prognosis of the case and the ability of the

clinician to properly treat traumatic injuries. The website creates the opportunity for the clinician to practice a more evidence-based or consensus-based approach to dental trauma.

Primary Treatment

Primary treatment is the urgent care provided as soon as possible after a traumatic incident. Generally, this type of treatment is time dependent, and the outcomes are more positive with immediate treatment. In addition to crown fractures and crown fractures with pulp exposure, primary care also involves treat-

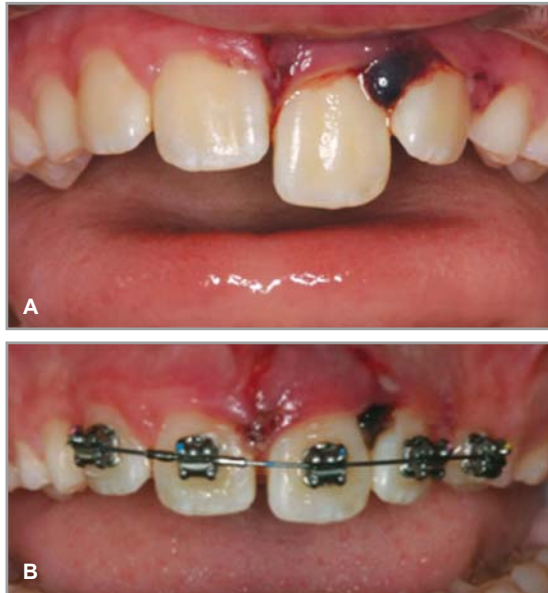


Figure 7. (A) A patient who suffered a lateral luxation and extrusive injury. (B) Self-ligating brackets were placed, and the tooth was repositioned after 3 days.

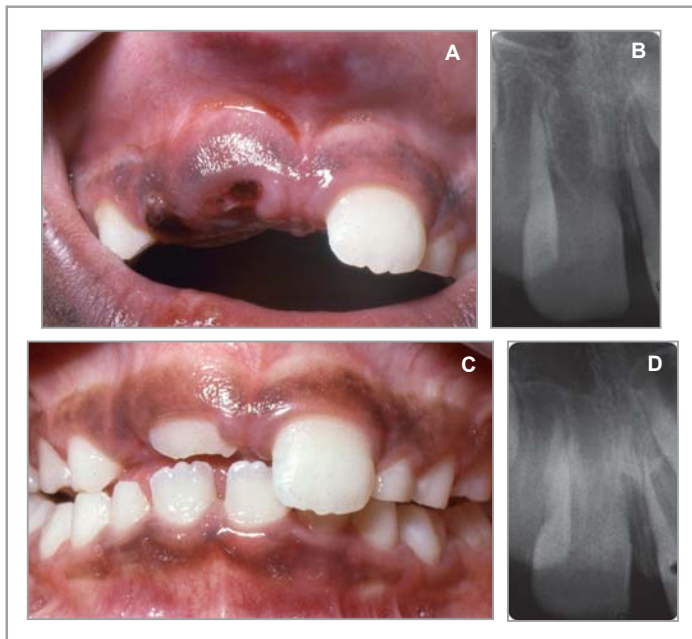


Figure 8. (A) Patient demonstrating intrusion and (B) immature root development that was confirmed radiographic ally. (C) The tooth was left to re-erupt and did (D), which was confirmed radiographically.

ment of a displaced tooth (lateral, intrusive, and extrusive luxation or avulsion). When a tooth has been displaced, the clinician treats the displacement by placing the tooth back into proper position. Once the tooth is positioned, it is splinted to hold the tooth in position. Active orthodontic treatment is not part of primary care.

Secondary Treatment

The secondary level of treatment consists of monitoring the pulp and periodontal tissues for healing and treatment. It also involves orthodontic treatment of displaced teeth.

The number one goal for the clinician is to provide treatment that will maximize the healing capabilities of both the pulpal and periodontal ligament tissues. Outcomes will vary depending on the amount of tooth displacement, the developmental stage of the tooth, and splinting times and methods. A comprehensive review of these variables is provided in the book on dental trauma by Andreasen et al.¹⁵

The treatment of tooth displacement becomes more complicated when the time interval between trauma and treatment is extended. Although one would suspect the patient would present to the dentist in a timely fashion, this is often not the case. Extended waiting time in emergency departments and the inability of the emergency department personnel to provide definitive dental treatment extend treatment time. In some cases, the patient requires medical care before dental care to stabilize or treat injuries such as associated head trauma. In other instances, dentists not familiar with trauma recommend no immediate treatment or delay treatment of displaced teeth. In these cases in which there has been a great deal of time between trauma and treatment, there have been considerable swelling and fluid accumulation around the injured tooth. At other times, healing has begun, with soft tissue clotting and reorganization occurring in the trauma area. In either case, the displaced tooth is very difficult, if not impossible, to reposition and splint without additional luxation or extraction and reimplantation. Regardless, it is difficult to place enough pressure on the tooth to completely reposition the tooth in its original position.

In these types of situations, the clinician may wish to consider orthodontic treatment as an adjunct to treatment of dental trauma. The orthodontic treatment of displaced teeth can help in multiple ways. First, the tooth can be repositioned with an extremely light force compared with a heavier and more forceful digital manipulation. A light flexible wire can provide a more gentle seating force during an extended time period, which allows the tooth to be completely repositioned. The importance of the light repositioning force cannot be overstated. Trope wrote that the goal of dental trauma treatment is to optimize healing after a traumatic injury. It is essential to ensure that the surface area of root damage is as small as possible. It is not possible to control the original physical damage to the root surface caused by the trauma itself, but posttrauma damages can be controlled with proper care.¹⁴

The second reason to consider orthodontic treatment is the extent of the trauma itself. In some cases, it is impossible to reposition the tooth accurately because the trauma has broken the facial plate of bone or disturbed the socket architecture to the point where it is difficult to replace the tooth in an ideal position. The use of light repositioning forces through reorganizing tissue will allow the doctor to eventually reposition the tooth into the correct position in relation to the other teeth and the occlusion. The bone can remodel with healing and recreate a facial plate and socket if the damage has not been too extensive.

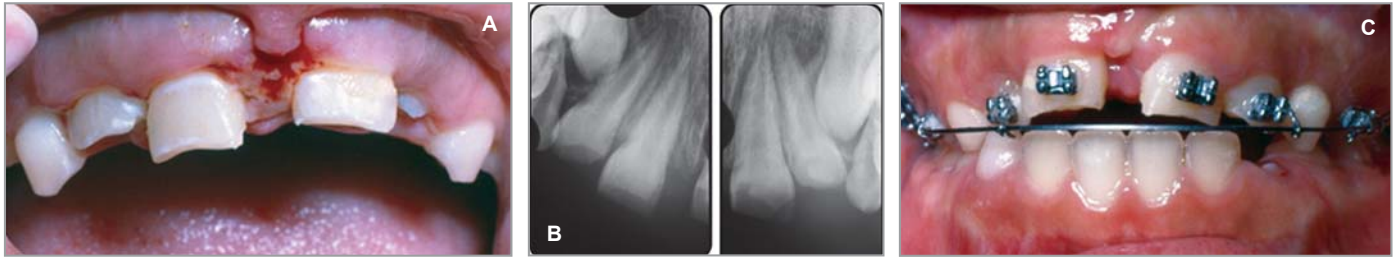

Figure 9. (A) All maxillary incisors except the right central have been intruded to some extent. (B) Radiographs show complete root formation and no fractures. (C) Teeth were extruded by using orthodontic appliances.

In the case of intrusion, the clinical examination or radiographs do not always reveal the true extent of the injury. Timely movement of the teeth can facilitate diagnosis and treatment of the tooth and provide access to the clinical crown of the tooth (Fig. 5). Furthermore, tooth movement can, according to some, reduce the possibility of ankylosis of the injured tooth.¹⁷

The last advantage of orthodontic treatment in trauma situations is often overlooked. It is rare that local anesthetic is necessary when the clinician places brackets and wires to reposition the teeth. In an already fearful child, this can often make the trauma experience more calming and more predictable if the child does not have to manage the fear of local anesthetic on top of everything else that has happened that day. Although this is not the sole reason to consider orthodontic treatment, it is definitely a good patient management tool.

Specific Indications for Orthodontic Treatment

An orthodontic trauma kit can be made in anticipation of trauma treatment. The kit should include orthodontic hand instruments, cheek retractors, self-etching primer or traditional etchant, self-ligating or twin brackets, preferably light flexible nickel-titanium (NiTi) wire, and a cell phone. Cheek retractors simply act as another set of hands and greatly simplify patient treatment and isolation. One approach to bracket placement is to use a self-etching primer rather than the more traditional method of acid etch, wash, and bonding agent application before placing brackets. It may be easier to maintain a blood-free zone to place the bracket with a self-etching primer because of the reduction in steps and time necessary to provide a good bonding surface. Alternatively, liberal use of an etchant can effectively cauterize the adjacent tissue and limit hemorrhage if use of the water and air is not aggressive but thorough. Self-ligating brackets seem to be the easiest to manage because the self-ligating feature ensures the bracket is either open or closed. This is important because the clinician can reliably know the tooth is properly ligated to the wire. It is also easier on the patient if the bracket can be opened or closed gently rather than having to be tied with a steel or elastomeric ligature. The ligature-tying process can add additional stresses or force to the teeth that can make the patient more uncomfortable. The NiTi wires provide light consistent forces and easy displacement into brackets. A cell phone is convenient for receiving photographs of the injury and directing the parent or caregiver before office contact.

Lateral Luxation

Laterally luxated teeth can be moved immediately. Before moving displaced, laterally luxated teeth, the clinician should identify stable, noninjured teeth on either side of the injured tooth to place brackets, so the injured tooth can be moved effectively. This is no different than selecting teeth to use for splinting. A

12- or 14-mil NiTi wire is typically used to reposition the tooth because of the low force and large range the wire delivers during an extended time period. Generally, the tooth is completely repositioned within the first 3–5 days, but longer times are

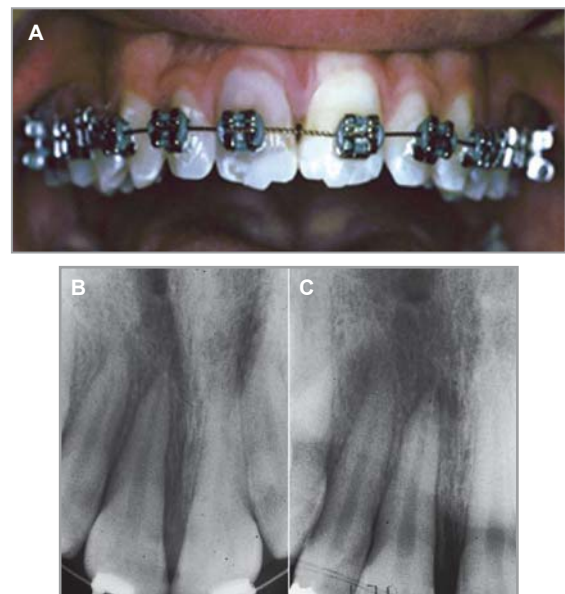


Figure 10. Patient experienced a concussion injury to the maxillary right central incisor while undergoing orthodontic treatment. (A) The archwire was changed to a lighter wire, the tooth was stabilized, and the radiograph revealed no pathology. Treatment progress continued within several weeks. (B and C) Follow-up radiographs revealed periapical pathology when exposed from multiple vertical angles. (B and C from Proffit WR, Fields HW, Sarver DM. Contemporary Orthodontics, 5th ed. St Louis, MO: Mosby; 2013.)

Table 1. SENSIBLE OPTIONS FOR TRACTION OF POSTTRAUMA TEETH

Method	Tissue compatibility	Hygienic	Efficient	Ease of fabrication
Elastomeric chain	+	0	0	-
Multiloop archwire	-	+	+	-
Superelastic continuous wire	+	+	-	0
Superelastic segmental overlay wire	+	+	+	0

+ = Good; 0 = neutral to fair; - = poor.

sometimes required. Because of the usual lingual direction of force, many laterally luxated teeth are displaced lingually and into crossbite or an anterior occlusal interference (Fig. 6). In either case, the clinician may elect to open the bite slightly with cement or composite on the posterior teeth. After the tooth has been repositioned, the orthodontic wire serves as a flexible or semi-rigid splint, depending on the size of the wire. Often in cases of alveolar fracture and displacement, a light flexible NiTi wire can be selected to reposition the teeth, and then a larger, more rigid beta titanium or stainless steel wire can be placed to stabilize the alveolar fracture. Because it is only a matter of opening the self-ligating bracket, this is a very simple procedure for both the clinician and the patient (Fig. 7).

Avulsion

Treatment of avulsed teeth is time dependent, and the sooner the tooth is replaced, the better the prognosis. Unfortunately, there are times when there is a delay between the avulsion and replacement of the tooth. Healing will have started, and it is difficult to reposition the tooth completely in the socket. In some cases, the tooth can be repositioned, but the hydraulic pressure of the blood in the socket prevents complete seating, or the oozing blood causes the tooth to float immediately out to the socket. In these cases, orthodontic treatment can be considered as described in lateral luxation injuries. Teeth are identified as anchor teeth on either side of the avulsion, and the brackets are placed on those teeth. The clinician must cradle the avulsed tooth in the socket and place a bracket on the tooth in ideal or near ideal position. The wire is gently inserted into the bracket, and the

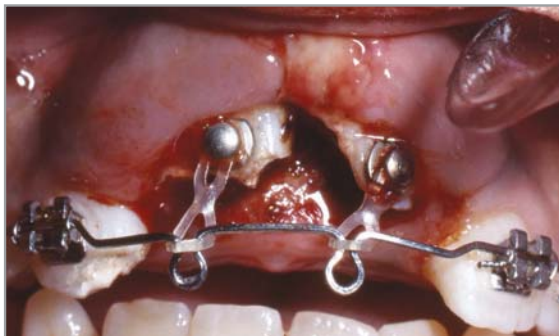

Figure 11. The heavy base wire with elastomeric chain attached for tooth moving force appears simple but can be difficult to fabricate. (From Proffit WR, Fields HW, Sarver DM. Contemporary Orthodontics, 5th ed. St. Louis, MO: Mosby; 2013.)

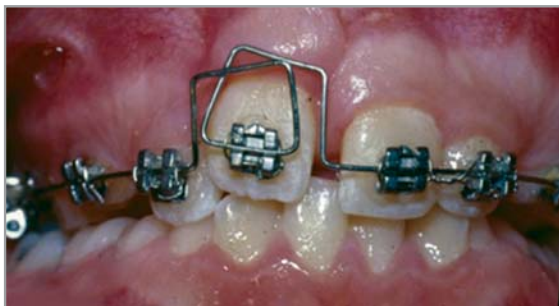

Figure 12. Multiloop archwires are too difficult for many clinicians to fabricate and, if not adjusted properly, can irritate the patient's soft tissue.

avulsed tooth is now stable and will reposition into the socket over time. Again, the clinician should expect the tooth to be completely seated in a 3- to 5-day period.

When pulpal tissue is managed for an avulsed tooth, it is advantageous to have the brackets in place and the wire stabilizing the tooth. There is no need to remove the brackets and wire to place the rubber dam or isolate the tooth for treatment. In fact, it is often desirable to have the splint or orthodontic appliances in place to ensure the tooth remains stable during the endodontic treatment.

Intrusion

The treatment of intrusive traumatic injuries with orthodontic appliances has been studied more closely than any of the other injuries. Despite that fact, there is still some uncertainty how to best treat an intrusion injury.

Treatment for dental intrusion is based on several factors. The first is the stage of development of the tooth. If the tooth is immature (incomplete root formation), it is suggested to monitor the tooth and wait for spontaneous re-eruption.¹⁸⁻²⁰ Usually 4-6 weeks should provide an adequate opportunity for spontaneous eruption. This approach yielded the lowest number of complications (pulp and periodontal ligament)¹⁸⁻²⁰ (Fig. 8).

If the tooth is mature (complete root formation), it is suggested that a more immediate approach to repositioning should be considered.¹⁸⁻²⁰ Guidelines suggest that the clinician observe intrusions of 3 mm or less for spontaneous re-eruption for several weeks. A smaller amount of intrusion has a better prognosis than one with significant intrusion. Developing ankylosis may be a factor, so longer observation than 3 weeks can be risky, especially if access for pulpal therapy is compromised. When the tooth is intruded $\leq 6-7$ mm, orthodontic treatment is generally

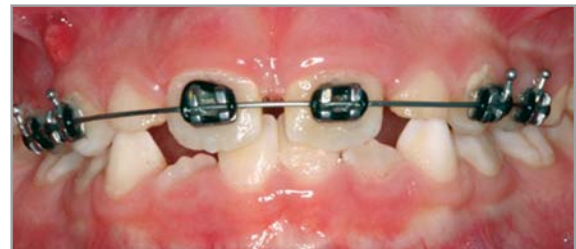


Figure 13. Continuous superelastic archwires can effectively move displaced teeth. They provide light continuous forces and require little adjustment. Teeth in both the anchorage and active portions of the wire may move and cause unanticipated changes.

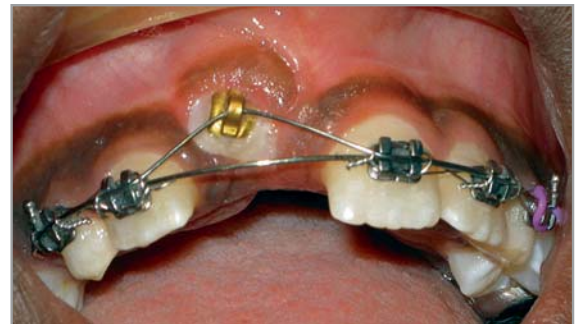

Figure 14. Using a formable base wire and a segment of superelastic wire tied loosely with steel ligatures will provide a light continuous force, stability in the anchorage units, and reduced friction. (From Proffit WR, Fields HW, Sarver DM. Contemporary Orthodontics, 5th ed. St. Louis, MO: Mosby; 2013.)

the first choice. The studies of intrusive injuries and orthodontic repositioning are difficult to compare, because there are so many

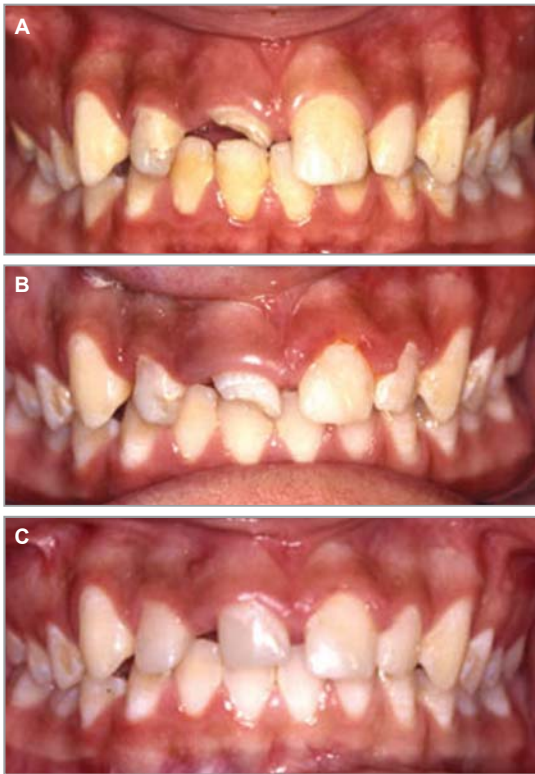

Figure 15. (A) Teeth that have extensive crown fractures that extend subgingivally (B) may need to be extruded. (C) Crown lengthening and a temporary restoration are in place.

different starting times for treatment. A recent animal study may shed more light on when to begin treatment. The authors discovered that the sooner orthodontic treatment was initiated in dogs with intruded teeth, the less replacement resorption was evident.¹⁷ The numbers of intruded teeth in the study were limited, so conclusions cannot be applied with certainty. The literature suggests that intruded maxillary anterior teeth can be moved into position approximately 9 of 10 times by using orthodontic force.¹⁹ This usually results in less destruction of the marginal gingival tissue than the use of surgical repositioning with a forceps (Fig. 9).

If the intrusion is greater than 6–7 mm, spontaneous re-eruption is not considered; rather, immediate surgical repositioning and orthodontic repositioning are the obvious choices. Surgical repositioning is usually favored because of the magnitude of the required movement, number of appointments, and the time limit imposed to open the tooth for pulpal therapy (2–3 weeks). Extraction also may need to be considered.²⁰

Trauma during Orthodontic Treatment

Teeth experiencing trauma during orthodontic treatment are significantly more likely to have pulpal necrosis than orthodontic or trauma only teeth.²¹ Furthermore, teeth with extrusion, intrusion, or lateral luxation were significantly more likely to have pulpal necrosis than teeth experiencing injury only to the crown.²¹ Total pulpal obliteration appeared to be another significant factor in pulpal necrosis. Certainly monitoring these teeth at defined intervals with radiographs is indicated.

Although there is no evidence to provide the clinician with definitive answers, the prudent clinician will reassess the case after the traumatic injury (Fig. 10). Depending on the extent of the injury and the current stage of treatment (beginning, middle, and finishing), the clinician may elect to discontinue treatment, modify treatment, or finish as planned.

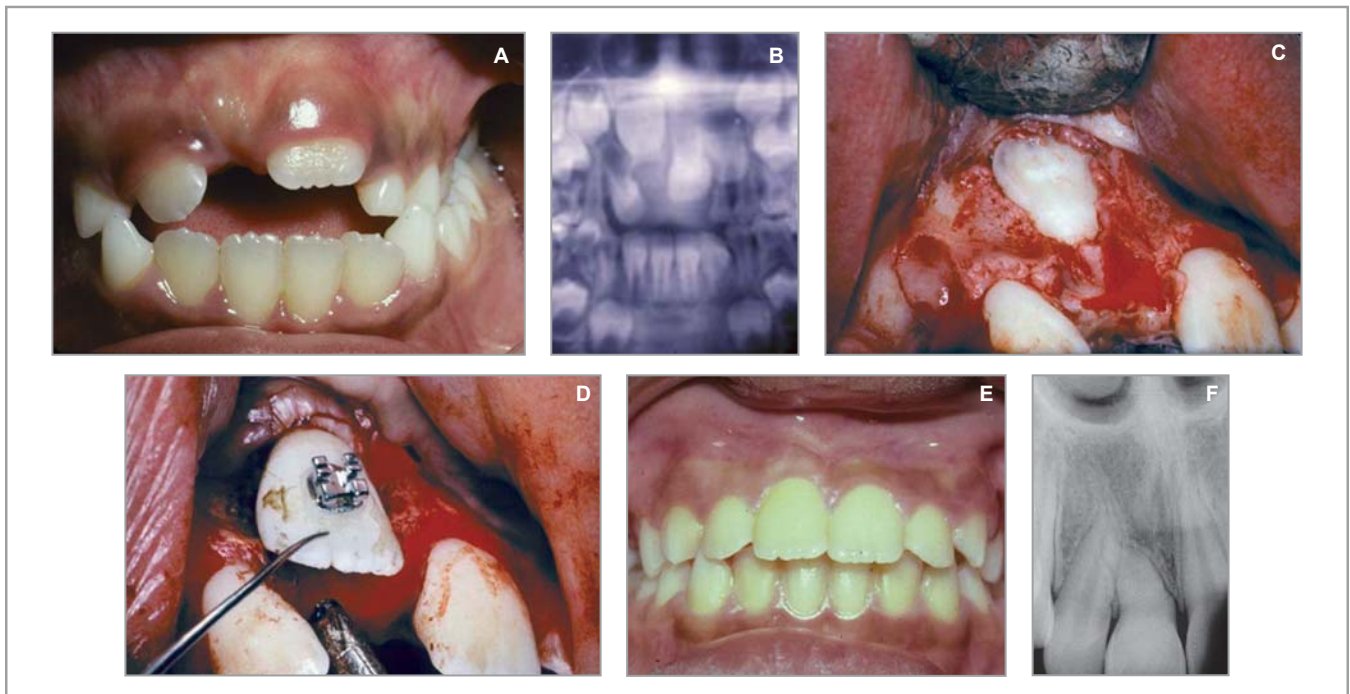


Figure 16. (A–F) Some teeth that are displaced can benefit from reorientation (transplantation in situ). (A) Unerupted maxillary right central incisor. (B) Panoramic radiograph showing the inverted tooth. (C) Surgical exposure of the unerupted tooth. (D) Surgical reorientation of the tooth, followed by bonding a bracket. (E) Tooth in final position after orthodontic traction. (F) Periapical radiograph showing shortened and dilacerated but functional root.

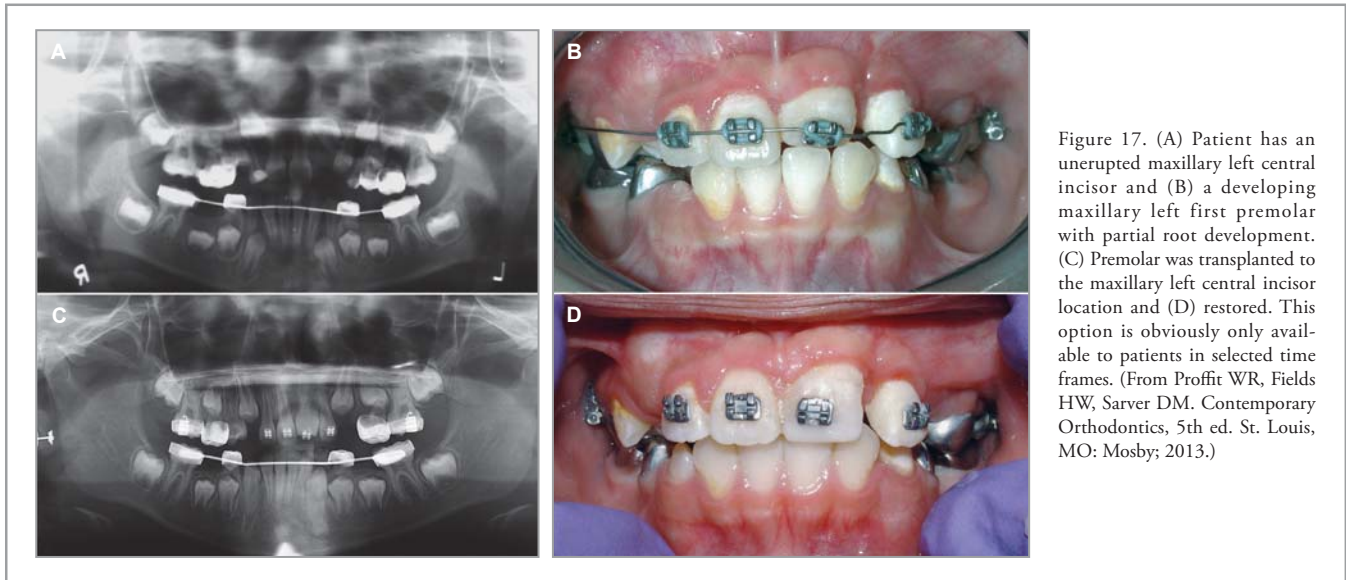


Figure 17. (A) Patient has an unerupted maxillary left central incisor and (B) a developing maxillary left first premolar with partial root development. (C) Premolar was transplanted to the maxillary left central incisor location and (D) restored. This option is obviously only available to patients in selected time frames. (From Proffit WR, Fields HW, Sarver DM. Contemporary Orthodontics, 5th ed. St. Louis, MO: Mosby; 2013.)

Sensible Biomechanics for Secondary, Posttrauma Orthodontic Tooth Movement

An issue that immediately presents itself is how teeth should be moved during the immediate posttrauma period if that is required.²² Most likely it will be either facial movement of lingually positioned or extrusion of intruded incisors. These situations present slightly different challenges, but in both instances, the clinician wants a method that is compatible with the tissue, hygienic, efficient with light, sustained forces, and easy to fabricate. Although many possibilities exist, which range from intraoral elastics placed by the patient to cantilever beams, only a few are sensible. Most practitioners gravitate to elastomeric chains, multiloop archwires, superelastic flexible continuous wires, or superelastic segmental overlay wires. Table 1 summarizes all the attributes of each method. Although the concept of a heavy straight wire bonded to the teeth with elastomeric chains extended to the teeth appears simple, its adjustment and placement are a challenging way to provide heavy, rapidly decaying forces to the teeth (Fig. 11). Multiloop archwires are simply too difficult for many clinicians to bend and can cause additional soft tissue irritation (Fig. 12). The new superelastic wires cannot be formed, so no wire bending is required. They provide light, continuous forces (Fig. 13) and can be supported as segmental wire to counteract reactive forces with heavier continuous wires (Fig. 14). Some superelastic wires undergo thermal transformation that can even further enhance their properties and usefulness. Superelastic wires used appropriately can simplify posttrauma tooth movement and make it possible for most practitioners who want to perform this type of treatment.

Tertiary Posttrauma Treatment

Essentially, tertiary posttrauma treatment addresses the ramifications of orthodontic treatment for previously traumatized teeth. Timing of orthodontic treatment after the trauma is an unresolved issue. Kindelan et al²³ suggest 3 months of waiting before orthodontic treatment for minor injuries and 6 months to 1 year for more severe injuries, on the basis of expert opinion.

There are several kinds of trauma that patients may have encountered in the past. For patients with complete root formation and crown only trauma, the most frequent type, tipping movements, resulted in a significant increase in both pulp path-

ology (7%) and root resorption (28%) when compared with orthodontic treatment for nontraumatized teeth and control teeth.²⁴ These results were based on clinical, radiographic, and electric pulp testing. Malmgren et al²⁵ found 39% prevalence of

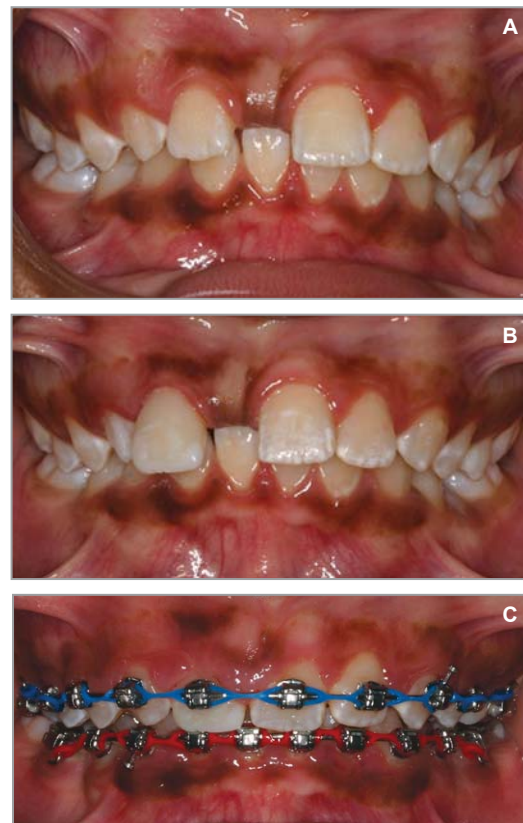

Figure 18. (A) Patient who lost a maxillary right central incisor to trauma at age 7. Because of crowding and protrusion, the treatment plan included premolar extractions on the unaffected maxillary left quadrant and substitution of the maxillary right lateral incisor as the right central incisor. (B) The maxillary right lateral incisor was restored before orthodontic treatment to the size of the contralateral central incisor. (C) Substitution space closure in progress.

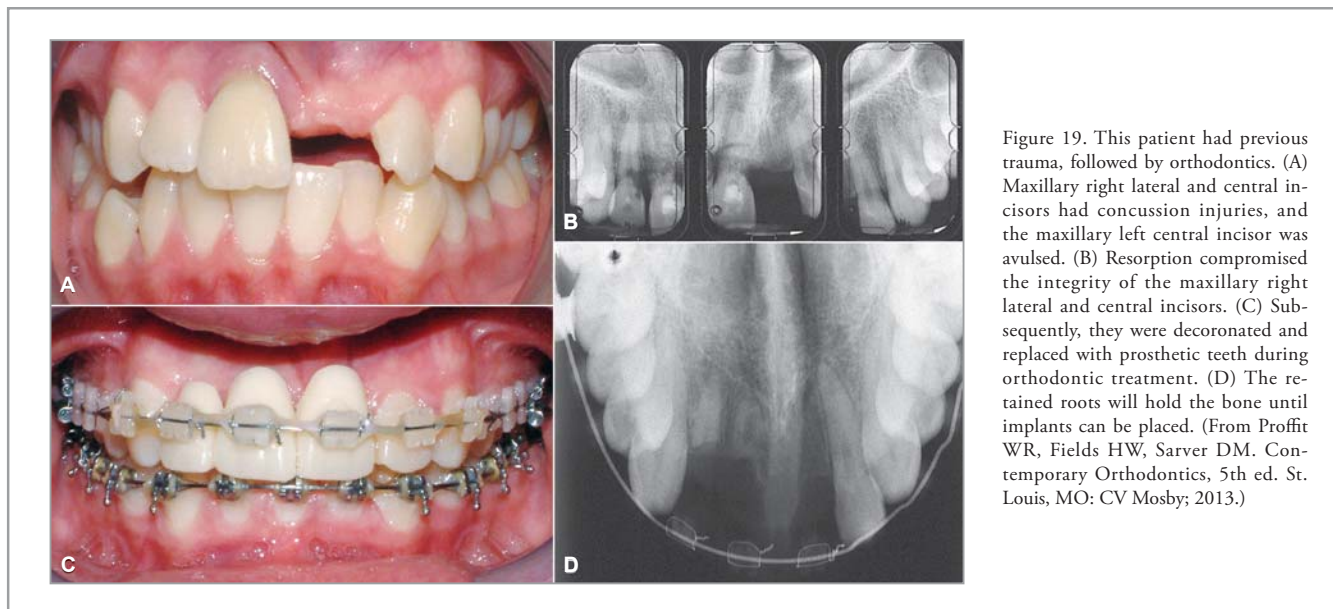


Figure 19. This patient had previous trauma, followed by orthodontics. (A) Maxillary right lateral and central incisors had concussion injuries, and the maxillary left central incisor was avulsed. (B) Resorption compromised the integrity of the maxillary right lateral and central incisors. (C) Subsequently, they were decoronated and replaced with prosthetic teeth during orthodontic treatment. (D) The retained roots will hold the bone until implants can be placed. (From Proffit WR, Fields HW, Sarver DM. Contemporary Orthodontics, 5th ed. St. Louis, MO: CV Mosby; 2013.)

resorption for this type of injury during orthodontic treatment but no difference when compared with orthodontically only treated teeth. Interestingly, the first study began orthodontic treatment approximately 8 months after injury, on the average, and in the second study, the waiting period was approximately 2 years. These data confuse the issue of a recommended waiting time.

When previously traumatized teeth were extruded, those with periodontal injuries (concussions, luxations, lateral luxations, intrusions, extrusions, and avulsions) had significantly more pulp pathology.²⁶ Those with crown only or crown and pulp trauma showed no differences from either orthodontics or trauma only teeth.

Previously traumatized teeth that are intruded with orthodontics have significantly more pulpal necrosis, and those with total pulpal obliteration are significantly more likely to have necrosis than those without or those having partial obliteration.²⁷ The findings from this investigation leave the distinct impression that moving previously traumatized teeth will likely have, at the least, pulpal pathologic changes. Thus, periodic radiographic monitoring of the affected teeth is merited.

Endodontically Filled Teeth

It appears that teeth with previous pulpal pathology including those with a history of trauma, when observed and deemed to be asymptomatic and free from inflammatory and replacement resorption, can be moved orthodontically with little consequence.²⁸ In fact, some data show these teeth have less apical, orthodontically induced root resorption than contralateral control teeth.²⁹

Orthodontics Related to Tertiary Care (Interdisciplinary) Posttrauma Treatments

Tertiary care is provided months to several years after the trauma when the outcome of the trauma is evident. The most obvious example of this type of treatment is extrusion of crown and crown-root fractures for crown lengthening and restoration (Fig. 15).

Orthodontic treatment can be integrated with other disciplinary care to provide innovative solutions after trauma. One option reported in the literature is the transplantation *in situ* of traumatically affected teeth (Fig. 16).²² These teeth often have been reoriented within the alveolus and have dilacerated roots. Careful surgical technique can be used to reorient the tooth, thus saving valuable treatment time while bonding an attachment with chain for traction. These teeth can then be moved orthodontically into the arch with good periodontal and radiacular results. Previously hopeless teeth can be esthetic and functional.

Traditional tooth transplantation of premolar teeth to the anterior segments is another solution when anterior teeth are lost to trauma (Fig. 17).³⁰ Transplanting teeth with incomplete root formation, placing them in infraocclusion, and subsequently moving them orthodontically approximately 3–4 months after the surgery can provide ultimately good esthetics, periodontal architecture, and function when combined with excellent restorative care. This type of treatment must be anticipated and can only be attempted during certain windows of time with the developing teeth.

Another option for the post-dental trauma patient is to substitute teeth for the missing tooth so that implants or fixed or removable prosthodontics are not required.³¹ This solution demands that careful orthodontic positioning is combined with excellent restorative care to provide a good result. Often asymmetric tooth movement is required so that anchorage considerations and even temporary anchorage devices are required to achieve the desired results (Fig. 18).

In some cases, restorative replacement of the tooth with an implant must be considered. If the root portion of the tooth can be saved, the injured tooth can be decoronated (clinical crown removed), and the root portion can be retained to help maintain bone until growth is complete and the implant can be placed³² (Fig. 19).

Acknowledgments

The authors report no conflicts of interest related to this study.